

BMB Reports – Manuscript Submission

Manuscript Draft

Manuscript Number: BMB-21-055

Title: Olfactory pathology in Alzheimer's disease: a sign of ongoing neurodegeneration

Article Type: Mini Review

Keywords: Alzheimer's disease; olfactory dysfunction; pathophysiology; olfactory epithelium; olfactory bulb

Corresponding Author: Cheil Moon

Authors: Gowoon Son^{1,2,3}, Ali Jahanshahi^{2,3}, Seung-Jun Yoo^{4,5}, Jackson Boonstra^{2,3}, David Hopkins⁶, Harry Steinbusch^{1,3,#}, Cheil Moon^{1,4,*,#}

Institution: ¹Brain & Cognitive Sciences, DGIST,

²Department of Neurosurgery, Maastricht University Medical Center+,

³School for Mental Health and Neuroscience, Maastricht University,

⁴Convergence Research Advanced Centre for Olfaction, DGIST,

⁵Neurogenetics, Max Planck Research Unit,

⁶Department of Medical Neuroscience, Dalhousie University,

Review Article

Olfactory pathology in Alzheimer's disease: a sign of ongoing neurodegeneration

Gowoon Son ^{1,2,3}, Ali Jahanshahi; Ph.D. ^{2,3}, Seung-Jun Yoo; Ph.D. ^{4,5}, Jackson T. Boonstra ^{2,3}, David A. Hopkins; Ph.D. ⁶, Harry W. M. Steinbusch; Ph.D. ^{1,3,*} and Cheil Moon; Ph.D. ^{1,4,*}

¹ Dept. of Brain & Cognitive Sciences, Graduate School, Daegu Gyeongbuk Institute of Science and Technology (DGIST), Daegu, Republic of Korea.

² Dept. Neurosurgery, MUMC+, Maastricht, the Netherlands.

³ School for Mental Health and Neuroscience, Maastricht University, Maastricht, the Netherlands.

⁴ Convergence Research Advanced Centre for Olfaction, DGIST, Daegu, Republic of Korea.

⁵ (Current address) Max Planck Research Unit for Neurogenetics, Frankfurt, Germany.

⁶ Department of Medical Neuroscience, Faculty of Medicine, Dalhousie University, Halifax, Canada.

* These authors contributed equally.

* Correspondence: Cheil Moon; Tel.: +82-53-785-6101 and Harry W. M. Steinbusch; Tel.: +31-6-1100-4797

Abstract

Olfactory neuropathology has shown to be a cause of olfactory loss in Alzheimer's disease (AD). Olfactory dysfunction is also associated with memory and cognitive dysfunction and has been considered an incidental finding of AD-dementia. Here we review neuropathological research on the olfactory system in AD considering both structural and functional evidence. Experimental and clinical findings identify olfactory dysfunction as an early indicator of AD. In keeping with this, amyloid- β production and neuroinflammation have shown to be related to underlying causes of impaired olfaction. Notably, physiological features of the spatial map in the olfactory system suggest the evidence of ongoing neurodegeneration. The aim of this review is to examine olfactory pathology findings essential to identifying mechanisms of olfactory dysfunction in the development of AD in hopes of supporting investigations leading towards revealing potential diagnostic methods and causes of early pathogenesis in the olfactory system.

Keywords: Alzheimer's disease; olfactory dysfunction; pathophysiology; olfactory epithelium; olfactory bulb; olfactory sensory neuron

Running title: Olfactory neuropathology in Alzheimer's disease

Introduction

Alzheimer's disease (AD) is a progressive neurodegenerative disorder and one of the most prevalent forms of dementia (1). Major symptoms are known to include memory loss and cognitive dysfunction. Several comorbidities in AD often coexist or are prominent, such as depression, circadian rhythm or sleep disturbances, and sensory-perceptual problems (2-4). Among other AD symptoms, olfactory dysfunction is seen not only as a highly prevalent symptom in AD (5) but also as an early diagnostic biomarker (6). That is, olfactory dysfunction is present in the early stages of AD and in probable AD patients who have mild cognitive impairment (MCI) (7). Therefore, olfactory deficits in AD have received increasing attention over the past few years in fundamental to clinical research. Because the representative pathologic hallmarks of AD are amyloid plaques and neurofibrillary tangles as well as brain atrophy (8), characterization of such pathological alterations in the olfactory system have been explored in an attempt to identify early stages of AD.

In brief, the olfactory system transmits chemical signals from the sensory epithelium and bulb to the olfactory cortex, following a serial synaptic interface (9-11). The olfactory bulb is the convergence of the peripheral olfactory system and the central subcortical systems that interconnect the olfactory sensory neuronal axons and the mitral cell dendrites. When studying olfactory dysfunction in AD, recent research efforts have implicated cortical olfactory regions (12, 13). Although several studies have reported clear pathogenesis in the olfactory sensory neurons (OSN) as well as olfactory bulbs (OB) in both rodent and human subjects (14, 15), little is revealed about the roles of the olfactory epithelium (OE) and the OB in AD progression.

Herein, we review literature on olfactory dysfunction in AD in order to examine how anatomical and physiological characteristics are disrupted in OSNs and OB and how that contributes to olfactory dysfunction in AD. In agreement with a recent review (16), we suggest a mechanism of olfactory impairment involving OE and OB neurodegeneration. Pathophysiologic findings are mainly from human studies, whereas cellular, molecular, and mechanistic evidences come mostly from rodent research. The significance of the peripheral olfactory (including the OE and a part of OB) degeneration in smell dysfunction in AD is then discussed.

Methods

A systematic search using PubMed for pathophysiologic findings underlying olfactory dysfunction in AD describing in rodent and human studies was conducted. The search was conducted within English literature published up to March 2021 using the following search terms: "Alzheimer's disease", "olfactory dysfunction", "Alzheimer's pathology", "olfactory system". Keywords were used independently and in various combinations. Research articles and reviews obtained were mainly published within the previous five years. Additional articles were added following a cross-reference search within review and original articles.

The neuropathology of Alzheimer's disease

AD is progressive and incurable neurodegenerative disease that can be characterized neuropathologically by protein accumulation including amyloid plaques and neurofibrillary tangles (17). Amyloid plaques are composed of misfolded amyloid- β ($A\beta$) proteins and are first found in the basal temporal cortex and orbitofrontal cortex, then progress to the neocortex, basal ganglia, hippocampal formation and the amygdala as AD progresses (17). Neurofibrillary tangles made of tau inclusions appearing in the locus coeruleus and entorhinal cortex, then spread to the neocortex and hippocampal formation throughout the brain (18). As a result of the increasing distribution of the protein aggregates, AD patients show brain atrophy as a pathological feature with severe memory and cognitive impairment as clinical symptoms (19).

Current clinical trials are assessing the ability of various interventions to reduce cognitive deficits and progressive neural impairment of patients with AD (20). Because neuronal injury is currently irreversible, identifying appropriate diagnostics, interventions, and treatment methods for AD is essential. Epidemiological studies indicate that olfactory dysfunction can predict cognitive decline (21) and Murphy (2019) reported that olfactory impairment has the potential to serve as an early indicator of AD (2).

Olfactory dysfunction in Alzheimer's disease

Anatomical and physiological alterations of the olfactory system in AD have been studied using various approaches (Tables 1 and 2). In AD patients, olfactory dysfunction usually appears as a reduced smelling ability known as hyposmia (22). Unlike congenital anosmia, olfactory deficits in AD patients appear during preclinical stages of the disease before the manifestation of cardinal AD symptoms. Specifically, decreased olfactory abilities have been shown in MCI and is proportional to cognitive impairment in amnesic MCI (aMCI) (6). Dysfunction of odor discrimination has therefore been suggested as a predictive behavioral measure for AD (22). For this reason, a particular "Odorant Item Specific Olfactory Identification" test has been proposed where certain odors are found to differentiate AD from general aging (23).

Because deficits in olfactory performance associated with impaired memory and cognitive function, deficits in olfaction in AD can be interpreted a consequence of a decline in perceptual processing and episodic memory (24). However, olfactory impairment also predicted cognitive deficits in non-demented adult population (25). Nonetheless, the AD pathogenesis in the olfactory system (see details "Neuropathology of the olfactory system in AD") supports the premise that olfactory deficits occur and progress prior to severe cognitive and memory decline in AD progression. Thus, attempts to characterize the early stages of AD have highlighted the interest in the olfactory system to reveal olfactory dysfunction pathophysiology in AD.

Organization of the olfactory system

Peripheral olfactory system

The processing of odor signals in mammals is initiated in the OE with OSNs being the primary neuron in the OE (Fig. 1). The somata of OSNs are organized in orderly layers based on maturity ranging from basal cells to matured-neurons (26). Once an odorant, *i.e.*, a gaseous molecule, or any airborne substances reaches the OE and binds to the odorant receptors located in the OSNs, the OSNs transduce the odor information to electrical signals that trigger neurotransmitter release in the OBs (10) (Fig. 1). Subsequently, those neuronal signals are transmitted to the olfactory cortex through the olfactory tract and tubercles (10). Mucus secreted by Bowman's glands protect the OE's structure and maintains its homeostasis (27).

Synaptic interface between peripheral and central components

Synaptic connectivity between the OSNs and central olfactory neurons in the OB glomeruli is essential for the initial olfactory processing of detection, identification, and discrimination of the odors (28). Thus, early synaptic dysfunction in the OSNs could lead to impaired olfactory information processing at higher levels thereby causing olfactory deficits. The structure of the OB shows a conserved laminar organization across species (29). Basically, the glomerulus, a neuropil structure of intertwining axons of OSNs, dendrites of periglomerular cells, and dendrites of mitral/tufted cells is the focus of initial processing of olfactory information (30). The glomeruli are considered the first recipient of sensory inputs as they host the first synapse in the olfactory system. In the glomerular network, which is well described in rodents, axons from OSNs expressing the same odorant receptor converge into approximately two of the 1,800 glomeruli in each OB (31, 32). The periglomerular cells are dopaminergic/GABAergic neurons that form an inhibitory feedback loop with the OSNs (33).

Central olfactory system

The olfactory system is anatomically distinctive and the projections are highly organized. The primary olfactory cortex includes the anterior olfactory nucleus, the olfactory tubercle, the piriform cortex, the entorhinal cortex, and the amygdala including orbitofrontal regions and the neural signals projecting to the secondary olfactory cortex in the orbitofrontal cortex (34) (Fig. 1). The afferent input from the OB is transmitted to the primary olfactory cortex through the olfactory tubercles composed of axons of mitral/tuft cells and GABAergic interneurons (35). These cells are differentiated from progenitor cells that have migrated from the subventricular zone (35). This track forms the first cranial nerve in the central nervous system (36).

Neuropathology of the olfactory system in AD

Olfaction can be compromised not only by a severe memory and cognitive disruption, but also by damaged olfactory pathways caused by injury or chronic exposure to toxic substances triggering AD pathogenesis. In this context, the olfactory system can be seen as a distinctly damaged site independent of the limbic system in terms of both AD pathologies and diagnostic opportunities.

Clinical studies have reported forms of proteinopathy in the peripheral olfactory system in AD patients. For instance, A β and p-tau-immunoreactivity have been found in the OE of AD patients (14). Interestingly, the degree of immunoreactivity correlated with the semiquantitative ratings were recorded for brain amyloid and tau-immunohistochemical staining (14). High levels of A β detected in nasal secretions may indicate that such proteins originate from the epithelium and peripheral olfactory neurons (37). In the glomeruli of the OB, A β and hyperphosphorylated tau have been detected, exhibiting progressive expression as *Braak* stages of AD pathology increased (17), but no significant changes were observed within the olfactory tract (13). Based on these findings, it seems that the peripheral olfactory system could be behind the generation of the toxic misfolded proteins that affect OSNs.

Moreover, both A β and tau have been observed in the cortical olfactory areas in AD patients, including both the olfactory peduncle and the anterior olfactory nucleus (12, 13), and the piriform cortex (38). The more recent study suggests that the olfactory system can be a hub to spread misfolded proteins to interconnected cortical areas and could seed the misfoldings of native proteins (12). In line with proteinopathy, patients with the apolipoprotein E4 (apoE4) allele, a well-known genetic factor linked with AD onset and a A β accumulation-triggering factor, are highly associated with olfactory deficits (39).

Mechanisms of the olfactory pathophysiology in AD

Amyloid precursor protein (APP) processing

In a transgenic mouse model for AD, enzyme expression involved in AD pathogenesis indicates a mechanism that may underly olfactory pathology. Positive A β immunoreactivity was found within the glomerular layer in young mice (40) and was shown to increase across the inner OB cell layers as the disease progressed (41). Expression of β -secretase, one of the main enzymes involved in amyloidosis, was only observed in the glomerular layer of the OB even in C57BL/6 mouse, a common inbred strain of laboratory mouse, showing that the glomerulus layer is likely the main region in A β production among OB layers (42).

A correlation between olfactory dysfunction and amyloid deposition was reported in APP/PS1 mice (43). Transgenic mice with conventional overexpressing humanized APP (hAPP) exhibited cell-autonomous apoptosis in either mature or immature OSNs and electron microscopy showed a decreased glomerular connectivity along with subcellular structural deficits (44). Furthermore, OSNs may play a role in independent APP processing. In one of the most well-characterized and widely used transgenic mouse models, the Tg2576 mouse model that overexpresses hAPP, the OE has been shown to exhibit higher expression level and activity of γ -secretase compared to other brain regions (45). Increased β -secretase levels in the olfactory glomerular layer have also been observed in Tg2576 (40).

Neuroinflammation

Apart from direct AD pathology, a number of environmental toxic factors can affect olfaction by causing damage to the OE, indicating that local toxicity is sufficient to impair smell. For instance, air-dust and nanoparticles have shown to damage OSNs directly causing oxidative stress and neuroinflammation similar to amyloid deposition (46). A variety of air pollutants trigger oxidative stress in the OE resulting in protein misfolding, mitochondrial dysfunction, and neuronal apoptosis. Furthermore, such factors recruit reactive microglia that can exacerbate inflammation by releasing pro-inflammatory cytokines such as TNF- α , IL- β , IFN γ (47). Interestingly, clinical studies have shown that one-fifth of diagnosed patients with AD have a history of allergy and chronic rhinitis that had required some sort of treatment (48).

Such toxic factors not only cause neuronal damage directly but could also exacerbate ongoing pathological process such as neuroinflammation (49) leading to further olfactory disturbances.

Spreading pathology along the neural circuit

The OB receives serotonergic projections from brainstem raphe nuclei which could form a reciprocal pathway that receives down-top signals through the olfactory cortex as well as modulating OSNs' synaptic activity (50). Given theories that emphasize the brainstem's role in AD pathology, raphe-OB connections could play a key function in AD pathology (51) because raphe pathology happens at early AD stages (52) implying that the OB is also involved in an early stage from both anterograde and retrograde influences. According to several other studies, the OB could deliver misfolded proteins into the brain. As evidence, A β that was injected into the OB of C57BL/6 mice was also found in other brain regions such as frontal cortex (53). A prion-like spreading of toxic molecules has been suggested to occur in the non-cortical olfactory structures that could cause olfactory abnormalities (54).

Physiology of spatially conserved map

Physiological functions are closely related to progressive pathological alterations in the olfactory system and can induce smell dysfunction in the onset of AD. The spatially conserved map in the olfactory system may play a critical role in the manifestation and progression of olfactory impairment in AD.

According to rodent studies, a physiologically conserved axis between the OE and OB can affect deteriorating or increasing AD pathogenesis and olfactory dysfunction. Naturally, the mammalian main olfactory system has a spatially-organized neuroregeneration and projection of OSNs. OSNs originate from progenitor cells located in the basal layer that proliferate (55) and mature by sending their axons to reach the OB. After development, OSNs can degenerate due to physical injury, cellular stress, aging, and AD related pathology. To maintain the structure of the OE, basal cells proliferate and differentiate into immature OSNs then to mature OSNs by rendering a synaptic interface with the mitral cellular dendrite in the OB. This process occurs throughout life and is called the replacement or turnover

of OSNs (56). Odorant receptor genes in the OSNs determine axonal projections to dorsal and ventral (ectoturbinate and endoturbinate in the OE's coronal plane) glomeruli in the OB (57) that show the topographic projection and subzonal organization (58, 59) (Fig. 2). OSN replacement is also regulated by a variety of physiological factors such as retinoic acid, a well-known cell differentiation promoter (60, 61). The two domains (endoturbinate-dorsal and ectoturbinate-ventral) summarize the zonal organization in the olfactory system and have different physiologies (Fig. 2). For example, when progenitor cells harvested from the dorsal OE were transplanted into the ventral region in mice, the transplant-derived neurons expressed a selective immunoreactive ventral marker OCAM (olfactory cell adhesion molecule) and lost a dorsal marker NQO1 (NADPH dehydrogenase) to match their new location (61). Additionally, Liberia et al (26) and Son et al (62) showed that OSNs in the ventral OE have a faster ratio of turnover (regeneration and degeneration) than those in the dorsal part suggesting repetitive OSN turnover triggers neuronal death of mature OSNs by driving excessive apoptosis, metabolic wastes, and neuroinflammation. Together, these events could result in further olfactory neuropathology promoting pathological processes such as APP expression and neuroinflammation.

It has been further suggested that the overexpression of β -secretase could impair olfactory function by causing cell death in ventrally projecting OSNs (40). In line with this, mRNA of β -secretase protein 1 (BACE1) was expressed in the ventral glomeruli of OB in C57BL/6 (42). In addition, oligomeric A β and β -secretase proteins were robustly expressed in the ventral parts of the glomeruli in Tg2576 (40). Calcium activity was decreased in the OSNs in ventral regions where oligomeric A β is highly overexpressed, and significantly damaged OSN turnover in the ventral OE than in the dorsal OE in 5xFAD with mutated human APP and presenilin 1 gene, a transgenic mouse model that can recapitulate AD-related early and aggressive phenotypes (62). Regarding neuroinflammation, Hasegawa-Ishii et al (63) reported intranasal administration of lipopolysaccharide induced an inflammatory response and synaptic loss in OSNs by triggering both microglia and astrocyte activation in the OB, and intriguingly, inflammatory monocyte immunoreactivity (Ly-6) was highly indicated in the ectoturbinate of the OE.

Extrinsic stimulation can affect different physiologies of the spatially conserved map of the olfactory system. OSNs are exposed to inhaled air and are therefore vulnerable to environmental factors such as air pollutants that cause DNA damage and cellular stress (64) while the ectoturbinate in the OE have a curved structure that enhances contact with inhaled air (65). OSNs are also sensitive to changes in air pressure and air flow (26, 66). Structural and functional changes of the spatially conserved map can impact neuronal stability in the olfactory system, and initiate a vicious cycle that could cause further damage. Further studies are required to define neuronal damage and excessive immune responses involved in the ectoturbinate and the endoturbinate.

The conserved map is strongly preserved across species (67, 68). Intriguingly, in a human postmortem study, the volume of ventral glomeruli was shown to be reduced in Parkinson's disease patients' OBs (69). However, many aspects remain to be explored in AD patients.

Clinical implications of olfactory pathophysiology in AD

The olfactory system has generated a great deal of interest in recent years as a novel tool for drug delivery and diagnosis in AD. Despite the advances in AD biomarker research, knowledge towards the applicability and accuracy of markers remains incomplete. An olfactory test for AD was developed by Richard L. Doty in 1984 (70), and has been applied in clinical research and diagnosis over the last 30 years. Olfactory dysfunction in AD exhibits specific features with clinical studies showing patients have difficulties identifying a specific subset of odorants (71). In particular, the peanut butter smell has been suggested as a reference test for AD patients require a closer distance to detect the smell of peanut butter compared to healthy controls (72). Partial hyposmia or specific anosmia is when one has an otherwise normal sense of smell but losses the ability to perceive one or more specific odors. A recent study using 5xFAD suggested the features and mechanism of the partial olfactory dysfunction demonstrating regionally specific A β accumulation influences partial olfactory dysfunction during early AD pathogenesis (62). These results suggest continued research on mechanisms within olfactory system pathophysiology can provide new light in early AD diagnoses.

Olfactory pathology allows us to speculate that the impaired OE include altered cellular and molecular components. In this regards, nasal fluid from the OE may feasibly contain high-throughput biological material information that mirrors AD pathological changes in the olfactory system (37) that could be linked to the OE. The composition of oligomerized A β proteins in nasal discharge has also shown to be closely correlated with cognitive function during AD progression (73). Thus, nasal fluid biomarkers could prove to be a candidate sourcing tool in AD similar to cerebrospinal fluid and plasma biomarkers. Correspondingly, the olfactory system may provide a new platform for conducting preclinical and clinical studies to improve diagnostics in AD and better understand the mechanisms behind neurodegeneration in AD.

Conclusion

This review highlights the significance of olfactory pathophysiology and olfactory dysfunction in AD progression. The olfactory function can be impaired by the AD pathologies derived by amyloidogenic APP processing and neuroinflammation in the olfactory system. In particular, the physiological features of the spatially conserved map in the OE and OB play a complex role in ongoing olfactory neurodegeneration that induces abnormal olfaction within AD. This review suggests olfactory pathology and neurodegeneration itself can be seen as the main underlying cause of olfactory dysfunction rather than it being derived from higher cortical area deficits seen throughout AD. Taken together, AD is an incurable and irreversible disease, but AD-related olfactory dysfunction provides clues towards diagnostic methods and gives insight into onset mechanisms in AD pathogenesis.

List of abbreviations

AD: Alzheimer's disease

OE: olfactory epithelium

OB: olfactory bulb

OSN: olfactory sensory neuron

MCI: mild cognitive impairment

hAPP: humanized amyloid precursor protein

aMCI: amnesic MCI

A β : β -amyloid

BACE1: β -secretase protein 1

APP/PS1: humanized amyloid precursor protein/presenilin 1 mutated

Declarations

Ethics approval and consent to participate: Not applicable

Consent for publication: Not applicable

Availability of data and materials: The data that support the findings of this study are available from the corresponding author upon reasonable request.

Acknowledgements: This work was supported by the Korea Health Industry Development Institute (HI18C0154) and Basic Science Research Program through the National Research Foundation of Korea (NRF) funded by the Ministry of Education (2020R1A6A1A03040516). The funding sources had no such involvement in study design; in the collection, analysis and interpretation of data; in the writing of the report; and in the decision to submit the article for publication.

Author Contributions: Gowoon Son: Conceptualization, Methodology, Investigation, Drawing figures, Writing-original draft preparation. Ali Jahanshahi: Conceptualization, Writing-reviewing and editing, Supervision. Seung-Jun Yoo: Conceptualization, Writing-reviewing and editing. Jackson T. Boonstra: Writing-reviewing and editing. David A. Hopkins: Writing-reviewing and editing, Harry W. M. Steinbusch: Writing-reviewing and editing, Supervision, Project administration. Cheil Moon: Writing-reviewing and editing, Supervision, Project administration, Funding acquisition.

References

1. Alzheimer's-Association (2021) 2021 Alzheimer's disease facts and figures. *Alzheimers Dement*
2. Murphy C (2019) Olfactory and other sensory impairments in Alzheimer disease. *Nat Rev Neurol* 15, 11-24
3. Ownby RL, Crocco E, Acevedo A, John V and Loewenstein D (2006) Depression and risk for Alzheimer disease: systematic review, meta-analysis, and metaregression analysis. *Arch Gen Psychiatry* 63, 530-538
4. Brzecka A, Leszek J, Ashraf GM et al (2018) Sleep Disorders Associated With Alzheimer's Disease: A Perspective. *Front Neurosci* 12, 330
5. Schubert CR, Carmichael LL, Murphy C, Klein BE, Klein R and Cruickshanks KJ (2008) Olfaction and the 5-year incidence of cognitive impairment in an epidemiological study of older adults. *J Am Geriatr Soc* 56, 1517-1521
6. Roberts RO, Christianson TJ, Kremers WK et al (2016) Association Between Olfactory Dysfunction and Amnesic Mild Cognitive Impairment and Alzheimer Disease Dementia. *JAMA Neurol* 73, 93-101
7. Vasavada MM, Martinez B, Wang J et al (2017) Central Olfactory Dysfunction in Alzheimer's Disease and Mild Cognitive Impairment: A Functional MRI Study. *J Alzheimers Dis* 59, 359-368
8. Jack CR, Jr., Wiste HJ, Therneau TM et al (2019) Associations of Amyloid, Tau, and Neurodegeneration Biomarker Profiles With Rates of Memory Decline Among Individuals Without Dementia. *JAMA* 321, 2316-2325
- 9.
10. Firestein S (2001) How the olfactory system makes sense of scents. *Nature* 413, 211-218
11. Gottfried JA (2010) Central mechanisms of odour object perception. *Nat Rev Neurosci* 11, 628-641
12. Ubeda-Banon I, Saiz-Sanchez D, Flores-Cuadrado A et al (2020) The human olfactory system in two proteinopathies: Alzheimer's and Parkinson's diseases. *Transl Neurodegener* 9, 22
13. Bathini P, Mottas A, Jaquet M, Brai E and Alberi L (2019) Progressive signaling changes in the olfactory nerve of patients with Alzheimer's disease. *Neurobiol Aging* 76, 80-95
14. Arnold SE, Lee EB, Moberg PJ et al (2010) Olfactory epithelium amyloid-beta and paired helical filament-tau pathology in Alzheimer disease. *Ann Neurol* 67, 462-469
15. Cao L, Schrank BR, Rodriguez S et al (2012) Abeta alters the connectivity of olfactory neurons in the absence of amyloid plaques in vivo. *Nat Commun* 3, 1009
16. Dibattista M, Pifferi S, Menini A and Reisert J (2020) Alzheimer's Disease: What Can We Learn From the Peripheral Olfactory System? *Front Neurosci* 14, 440
17. Thal DR, Rub U, Orantes M and Braak H (2002) Phases of A beta-deposition in the human brain and its relevance for the development of AD. *Neurology* 58, 1791-1800
18. Braak H and Braak E (1991) Neuropathological staging of Alzheimer-related changes. *Acta Neuropathol* 82, 239-259
19. DeTure MA and Dickson DW (2019) The neuropathological diagnosis of Alzheimer's disease. *Mol Neurodegener* 14, 32
20. Cummings J, Lee G, Ritter A, Sabbagh M and Zhong K (2020) Alzheimer's disease drug development pipeline: 2020. *Alzheimers Dement (N Y)* 6, e12050
21. Pankratz VS, Roberts RO, Mielke MM et al (2015) Predicting the risk of mild cognitive impairment in the Mayo Clinic Study of Aging. *Neurology* 84, 1433-1442
22. Vyhnalek M, Magerova H, Andel R et al (2015) Olfactory identification in amnesic and non-amnesic mild cognitive impairment and its neuropsychological correlates. *J Neurol Sci* 349, 179-184
23. Woodward MR, Hafeez MU, Qi Q et al (2018) Odorant Item Specific Olfactory Identification Deficit May Differentiate Alzheimer Disease From Aging. *Am J Geriatr Psychiatry* 26, 835-846

24. Wilson RS, Arnold SE, Tang Y and Bennett DA (2006) Odor identification and decline in different cognitive domains in old age. *Neuroepidemiology* 26, 61-67
25. Swan GE and Carmelli D (2002) Impaired olfaction predicts cognitive decline in nondemented older adults. *Neuroepidemiology* 21, 58-67
26. Liberia T, Martin-Lopez E, Meller SJ and Greer CA (2019) Sequential Maturation of Olfactory Sensory Neurons in the Mature Olfactory Epithelium. *eNeuro* 6
27. Solbu TT and Holen T (2012) Aquaporin pathways and mucin secretion of Bowman's glands might protect the olfactory mucosa. *Chem Senses* 37, 35-46
28. Storace DA and Cohen LB (2017) Measuring the olfactory bulb input-output transformation reveals a contribution to the perception of odorant concentration invariance. *Nat Commun* 8, 81
29. Burneister HP, Bitter T, Heiler PM et al (2012) Imaging of lamination patterns of the adult human olfactory bulb and tract: in vitro comparison of standard- and high-resolution 3T MRI, and MR microscopy at 9.4 T. *Neuroimage* 60, 1662-1670
30. Morrison EE and Costanzo RM (1990) Morphology of the human olfactory epithelium. *J Comp Neurol* 297, 1-13
31. Wachowiak M and Cohen LB (2001) Representation of odorants by receptor neuron input to the mouse olfactory bulb. *Neuron* 32, 723-735
32. Maresh A, Rodriguez Gil D, Whitman MC and Greer CA (2008) Principles of glomerular organization in the human olfactory bulb--implications for odor processing. *PLoS One* 3, e2640
33. Bonzano S, Bovetti S, Gendusa C, Peretto P and De Marchis S (2016) Adult Born Olfactory Bulb Dopaminergic Interneurons: Molecular Determinants and Experience-Dependent Plasticity. *Front Neurosci* 10, 189
34. Ramachandran VS (2002) *Encyclopedia of the human brain*, Academic Press, San Diego, Calif.
35. Sahay A, Wilson DA and Hen R (2011) Pattern separation: a common function for new neurons in hippocampus and olfactory bulb. *Neuron* 70, 582-588
36. Holbrook EH and Coelho DH (2020) Cranial Nerve Stimulation for Olfaction (Cranial Nerve 1). *Otolaryngol Clin North Am* 53, 73-85
37. Kim YH, Lee SM, Cho S et al (2019) Amyloid beta in nasal secretions may be a potential biomarker of Alzheimer's disease. *Sci Rep* 9, 4966
38. Saiz-Sanchez D, De la Rosa-Prieto C, Ubeda-Banon I and Martinez-Marcos A (2015) Interneurons, tau and amyloid-beta in the piriform cortex in Alzheimer's disease. *Brain Struct Funct* 220, 2011-2025
39. Murphy C, Bacon AW, Bondi MW and Salmon DP (1998) Apolipoprotein E status is associated with odor identification deficits in nondemented older persons. *Ann N Y Acad Sci* 855, 744-750
40. Yoo SJ, Lee JH, Kim SY et al (2017) Differential spatial expression of peripheral olfactory neuron-derived BACE1 induces olfactory impairment by region-specific accumulation of beta-amyloid oligomer. *Cell Death Dis* 8, e2977
41. Wesson DW, Levy E, Nixon RA and Wilson DA (2010) Olfactory dysfunction correlates with amyloid-beta burden in an Alzheimer's disease mouse model. *J Neurosci* 30, 505-514
42. Cao L, Rickenbacher GT, Rodriguez S, Moulia TW and Albers MW (2012) The precision of axon targeting of mouse olfactory sensory neurons requires the BACE1 protease. *Sci Rep* 2, 231
43. Yao ZG, Hua F, Zhang HZ, Li YY and Qin YJ (2017) Olfactory dysfunction in the APP/PS1 transgenic mouse model of Alzheimer's disease: Morphological evaluations from the nose to the brain. *Neuropathology* 37, 485-494
44. Cheng N, Cai H and Belluscio L (2011) In vivo olfactory model of APP-induced neurodegeneration reveals a reversible cell-autonomous function. *J Neurosci* 31, 13699-13704
45. Kim JY, Rasheed A, Yoo SJ et al (2018) Distinct amyloid precursor protein processing machineries of the olfactory system. *Biochem Biophys Res Commun* 495, 533-538
46. Cheng H, Saffari A, Sioutas C, Forman HJ, Morgan TE and Finch CE (2016) Nanoscale Particulate Matter from

- Urban Traffic Rapidly Induces Oxidative Stress and Inflammation in Olfactory Epithelium with Concomitant Effects on Brain. *Environ Health Perspect* 124, 1537-1546
47. Imamura F and Hasegawa-Ishii S (2016) Environmental Toxicants-Induced Immune Responses in the Olfactory Mucosa. *Front Immunol* 7, 475
 48. Bozek A, Bednarski P and Jarzab J (2016) Allergic rhinitis, bronchial asthma and other allergies in patients with Alzheimer's disease: unnoticed issue. *Postepy Dermatol Alergol* 33, 353-358
 49. Heppner FL, Ransohoff RM and Becher B (2015) Immune attack: the role of inflammation in Alzheimer disease. *Nat Rev Neurosci* 16, 358-372
 50. Steinfeld R, Herb JT, Sprengel R, Schaefer AT and Fukunaga I (2015) Divergent innervation of the olfactory bulb by distinct raphe nuclei. *J Comp Neurol* 523, 805-813
 51. Sakurai K, Shintani T, Jomura N, Matsuda T, Sumiyoshi A and Hisatsune T (2020) Hyper BOLD Activation in Dorsal Raphe Nucleus of APP/PS1 Alzheimer's Disease Mouse during Reward-Oriented Drinking Test under Thirsty Conditions. *Sci Rep* 10, 3915
 52. Michelsen KA, Prickaerts J and Steinbusch HW (2008) The dorsal raphe nucleus and serotonin: implications for neuroplasticity linked to major depression and Alzheimer's disease. *Prog Brain Res* 172, 233-264
 53. He B, Zheng M, Liu Q et al (2018) Injected Amyloid Beta in the Olfactory Bulb Transfers to Other Brain Regions via Neural Connections in Mice. *Mol Neurobiol* 55, 1703-1713
 54. Rey NL, Wesson DW and Brundin P (2018) The olfactory bulb as the entry site for prion-like propagation in neurodegenerative diseases. *Neurobiol Dis* 109, 226-248
 55. Brann JH, Ellis DP, Ku BS, Spinazzi EF and Firestein S (2015) Injury in aged animals robustly activates quiescent olfactory neural stem cells. *Front Neurosci* 9, 367
 56. Graziadei PP, Levine RR and Graziadei GA (1978) Regeneration of olfactory axons and synapse formation in the forebrain after bulbectomy in neonatal mice. *Proc Natl Acad Sci U S A* 75, 5230-5234
 57. Miyamichi K, Serizawa S, Kimura HM and Sakano H (2005) Continuous and overlapping expression domains of odorant receptor genes in the olfactory epithelium determine the dorsal/ventral positioning of glomeruli in the olfactory bulb. *J Neurosci* 25, 3586-3592
 58. Eerdunfu, Ihara N, Ligao B, Ikegaya Y and Takeuchi H (2017) Differential timing of neurogenesis underlies dorsal-ventral topographic projection of olfactory sensory neurons. *Neural Dev* 12, 2
 59. Levai O, Breer H and Strotmann J (2003) Subzonal organization of olfactory sensory neurons projecting to distinct glomeruli within the mouse olfactory bulb. *J Comp Neurol* 458, 209-220
 60. Login H, Haglin S, Berghard A and Bohm S (2015) The Stimulus-Dependent Gradient of Cyp26B1+ Olfactory Sensory Neurons Is Necessary for the Functional Integrity of the Olfactory Sensory Map. *J Neurosci* 35, 13807-13818
 61. Coleman JH, Lin B, Louie JD, Peterson J, Lane RP and Schwob JE (2019) Spatial Determination of Neuronal Diversification in the Olfactory Epithelium. *J Neurosci* 39, 814-832
 62. Son G, Yoo SJ, Kang S et al (2021) Region-specific amyloid-beta accumulation in the olfactory system influences olfactory sensory neuronal dysfunction in 5xFAD mice. *Alzheimers Res Ther* 13, 4
 63. Hasegawa-Ishii S, Shimada A and Imamura F (2017) Lipopolysaccharide-initiated persistent rhinitis causes gliosis and synaptic loss in the olfactory bulb. *Sci Rep* 7, 11605
 64. Calderon-Garciduenas L, Maronpot RR, Torres-Jardon R et al (2003) DNA damage in nasal and brain tissues of canines exposed to air pollutants is associated with evidence of chronic brain inflammation and neurodegeneration. *Toxicol Pathol* 31, 524-538
 65. Zhao K, Dalton P, Yang GC and Scherer PW (2006) Numerical modeling of turbulent and laminar airflow and odorant transport during sniffing in the human and rat nose. *Chem Senses* 31, 107-118

66. Oka Y, Takai Y and Touhara K (2009) Nasal airflow rate affects the sensitivity and pattern of glomerular odorant responses in the mouse olfactory bulb. *J Neurosci* 29, 12070-12078
67. Imai T, Sakano H and Vosshall LB (2010) Topographic mapping--the olfactory system. *Cold Spring Harb Perspect Biol* 2, a001776
68. Braubach OR, Miyasaka N, Koide T, Yoshihara Y, Croll RP and Fine A (2013) Experience-dependent versus experience-independent postembryonic development of distinct groups of zebrafish olfactory glomeruli. *J Neurosci* 33, 6905-6916
69. Zapiec B, Dieriks BV, Tan S, Faull RLM, Mombaerts P and Curtis MA (2017) A ventral glomerular deficit in Parkinson's disease revealed by whole olfactory bulb reconstruction. *Brain* 140, 2722-2736
70. Doty RL, Shaman P and Dann M (1984) Development of the University of Pennsylvania Smell Identification Test: a standardized microencapsulated test of olfactory function. *Physiol Behav* 32, 489-502
71. Tabert MH, Liu X, Doty RL et al (2005) A 10-item smell identification scale related to risk for Alzheimer's disease. *Ann Neurol* 58, 155-160
72. Stamps JJ, Bartoshuk LM and Heilman KM (2013) A brief olfactory test for Alzheimer's disease. *J Neurol Sci* 333, 19-24
73. Yoo SJ, Son G, Bae J et al (2020) Longitudinal profiling of oligomeric A β in human nasal discharge reflecting cognitive decline in probable Alzheimer's disease. *Sci Rep*
74. Thomann PA, Dos Santos V, Toro P, Schonknecht P, Essig M and Schroder J (2009) Reduced olfactory bulb and tract volume in early Alzheimer's disease--a MRI study. *Neurobiol Aging* 30, 838-841
75. Devanand DP, Liu X, Tabert MH et al (2008) Combining early markers strongly predicts conversion from mild cognitive impairment to Alzheimer's disease. *Biol Psychiatry* 64, 871-879
76. Woodward MR, Dwyer MG, Bergsland N et al (2017) Olfactory identification deficit predicts white matter tract impairment in Alzheimer's disease. *Psychiatry Res Neuroimaging* 266, 90-95
77. Khan A, Plana-Ripoll O, Antonsen S et al (2019) Environmental pollution is associated with increased risk of psychiatric disorders in the US and Denmark. *PLoS Biol* 17, e3000353
78. Cheng N, Jiao S, Gumaste A, Bai L and Belluscio L (2016) APP Overexpression Causes Abeta-Independent Neuronal Death through Intrinsic Apoptosis Pathway. *eNeuro* 3

Figure legends**Figure 1.**

Scheme of the olfactory system. (Left) Scheme of olfactory sensory neuron projections. Olfactory sensory neurons transduce odor information via electrical signals that trigger neurotransmitter release in the olfactory bulb. Mucus secreted by Bowman's glands protects the olfactory epithelium's structure and maintains homeostasis. (Right) Scheme of the olfactory system according to the process of olfaction. a. olfactory epithelium, b. olfactory bulb, c. olfactory peduncle, d. piriform cortex, e. amygdaloid complex, f. entorhinal cortex, g. hippocampal formation, h. thalamus.

Figure 2.

Scheme of spatially conserved map in the olfactory system. The zonal organization, endoturbinates-dorsal glomerulus axis (blue), and ectoturbinates-ventral glomerulus axis (red). The two drawings in blue and red are representations of two olfactory sensory neurons with the colors emphasizing the regional topography of sensory inputs to the olfactory bulb.

Tables

Table 1 Pathological alterations in the olfactory system of patients with Alzheimer's disease (AD).

Findings	Methods	Clinical stage	Measured ⁵ AD pathology	Refs.
Reduced ¹ OB volume and white matter of the olfactory tract	² MRI, ³ DTI 3T-MRI	⁴ aMCI	⁶ n/a	(74)
β_{1-42} , p-tau, and astrogliosis in the glomerular layer, anterior olfactory nucleus, olfactory tubercle	⁷ IHC	MCI, moderate-AD, severe-AD	β_{1-42} , p-tau, astrogliosis	(13)
β -amyloid aggregates, PHF-tau, and α -synuclein in the anterior olfactory nucleus	IHC	n/a	β -amyloid, ¹² PHF-tau, α -synuclein	(12)
β -amyloid, tau in the piriform cortex	IHC	AD	β -amyloid, tau	(38)
Deficit in olfactory identification	Olfactory identification test, DTI 3T-MRI	aMCI, AD, MCI- ⁸ DLB, MCI-AD	Lewy body	(6, 74-76)
Deficit in olfactory identification differentiated AD from aging	Olfactory identification test	aMCI, AD, healthy aging	n/a	(23)
Reduced ability to identify a specific subset of smell	Olfactory identification test	AD	n/a	(71, 72)
Impaired olfactory identification (proportional to cognitive impairment in aMCI)	Olfactory identification test	aMCI, non-aMCI	n/a	(22)
Implication: damaged ⁹ OSNs and olfactory malfunction following exposure to air-pollutants	Statistics, Epidemiology	n/a	n/a	(77)
One-fifth of allergic and chronic rhinitis patients develop AD	Medical examination, IgE assay	allergic diseases with AD	Inflammation	(48)
β -amyloid aggregates, PHF-tau, and α -synuclein in the ¹⁰ OE	IHC	AD, ¹¹ OND	β -amyloid, ¹² PHF-tau, α -synuclein	(14)
β -amyloid in nasal secretions	WB IME biosensor	AD, OND	β -amyloid	(37)
β -amyloid in nasal discharge (correlated with cognitive decline)	LC/MS WB IME biosensor	probable AD (mild, moderate AD)	β -amyloid (A β *56, A β O)	(73)
apoE4 correlated with odor identification deficits	Odor threshold test, Olfactory identification test	n/a	apoE4	(39)

¹ OB: olfactory bulb, ² MRI: magnetic resonance imaging, ³ DTI-3T: 3.0 Tesla diffusion tensor imaging, ⁴ aMCI: amnesic mild cognitive impairment, ⁵ AD: Alzheimer's disease, ⁶ n/a: non-applicable, ⁷ IHC: immunohistochemistry, ⁸ DLB: dementia with Lewy body, ⁹ OSN: olfactory sensory neuron, ¹⁰ OE: olfactory epithelium, ¹¹ OND: other neurodegenerative disease, ¹² PHF: paired helical filament.

Table 2 Pathological alterations in the olfactory system in mouse models of Alzheimer's disease (AD).

Findings	Methods	Strain (age)	Refs.
<ul style="list-style-type: none"> - Decreased ¹ OE thickness - Increased populations of ² TUNEL (+) cell - Decreased in number and length of dendritic spines - Deficit in olfactory behavior and β-amyloid deposition - Increased latency in finding buried food, reduced peanut butter preference 	³ IHC, TUNEL assay, ⁴ EM	⁵ Tg2576 (6, 12 ⁶ M) APP/PS1 (9M)	(40, 43)
<ul style="list-style-type: none"> - Distorted ultrastructure and subcellular components in the OE - Decreased mature ⁷ OSNs 	⁸ ELISA, IHC, ⁹ PCR, EM, ¹⁰ BrdU assay	¹¹ hAPP (3 ¹² w)	(44, 78)
<ul style="list-style-type: none"> - Earlier β-amyloid deposition in the olfactory system than brain region 	IHC, Thio-S staining	Tg2576 (3, 6, 16, 21M)	(41)
<ul style="list-style-type: none"> - Region specific APP processing - Restricted expression of β-secretase only in the olfactory glomerulus in the ¹³ OB 	¹⁴ WB, IHC, ¹⁵ ISH	Tg2576 (10M), ¹⁶ BACE null	(40, 42)
<ul style="list-style-type: none"> - Reduced response to odorants (only specific odorant) - Region specific calcium inactivation of OSN correlated with Region specific β-amyloid deposition - Deficits of turnover ratio of OE 	Odor detection test, Calcium imaging, IHC, TUNEL assay	Tg6799 (3M)	(62)
<ul style="list-style-type: none"> - Damaged OSNs and olfactory malfunction following exposure to air-pollutant nanoparticles 	IHC, PCR, WB, nitrite assay	C57BL6 (3M), Fischer 344 rats (12w)	(46)
<ul style="list-style-type: none"> - Aberrant OSNs projection to the glomeruli 	IHC, ISH, ¹⁷ AAV modulation,	Tg2576 (13, 24M)	(15)
<ul style="list-style-type: none"> - Higher expressions levels and activity of γ-secretase in the OE - β-amyloid (Aβ*56) accumulates more quickly in the OE 	IHC, TUNEL assay, EM	Tg2576 (10M),	(45)
<ul style="list-style-type: none"> - Correlation between deficit of olfactory habituation and spatial-temporal β-amyloid deposition - Deficit in odor investigation and habituation 	odor cross-habituation test	Tg2576 (3, 6, 16, 21M)	(41)
<ul style="list-style-type: none"> - Altered the OSN connectivity by inducing human β-amyloid - Decreased response to aversive odor in induced human β-amyloid condition 	IHC, ¹⁸ TMT assay, hidden food assay	¹⁹ CORMAP mouse, Tg2576 (13, 24M)	(15)
<ul style="list-style-type: none"> - Injected β-amyloid in the OB transferring to other brain region 	β -amyloid injection, IHC, TUNEL, WB	C57BL6 (7-8w)	(53)

¹ OE: olfactory epithelium, ² TUNEL (+): terminal deoxynucleotidyl transferase dUTP nick end labeling-positive. ³ IHC: immunohistochemistry, ⁴ EM: electric microscopy, ⁵ Tg: transgenic mouse, ⁶ M: months, ⁷ OSN: olfactory sensory neuron ⁸ ELISA: enzyme-linked immunosorbent assay ⁹ PCR: polymerase chain reaction, ¹⁰ BrdU: 5-bromodeoxy-2-deoxyuridine, ¹¹ hAPP: human amyloid precursor protein, ¹² w: weeks, ¹³ OB: olfactory bulb, ¹⁴ WB: western blot, ¹⁵ ISH: in situ hybridization, ¹⁶ BACE: β -site amyloid cleavage enzyme, ¹⁷ AAV: Adeno-associated virus, ¹⁸ TMT: 2,3,5-Trimethyl-3-thiazoline, ¹⁹ Conditional, Olfactory Sensory Neuron-Restricted Mosaic expression of APPsw and PLAP.

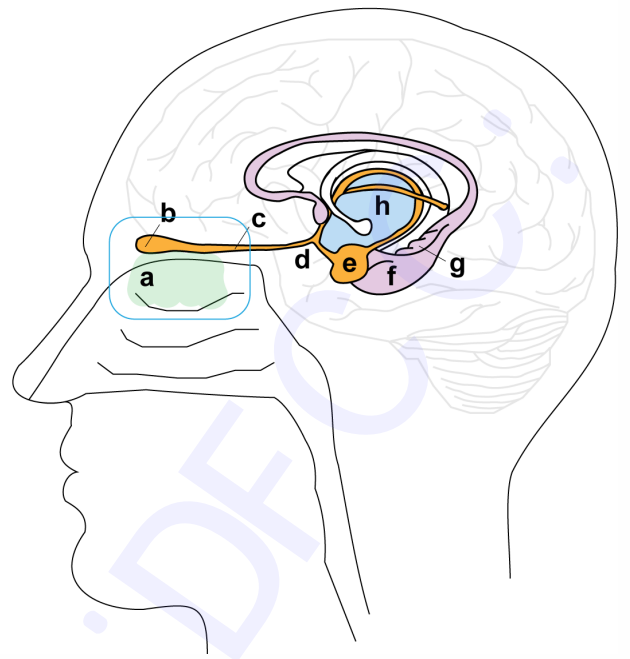
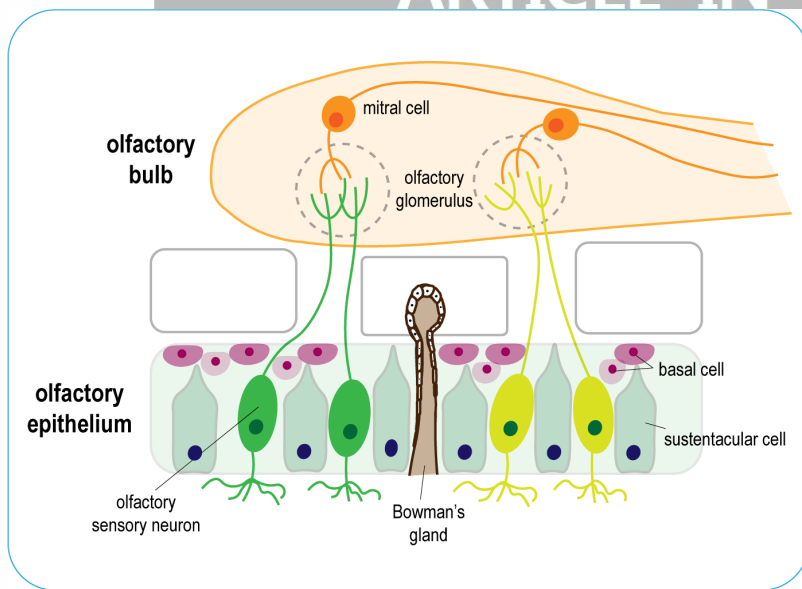


Fig. 1.

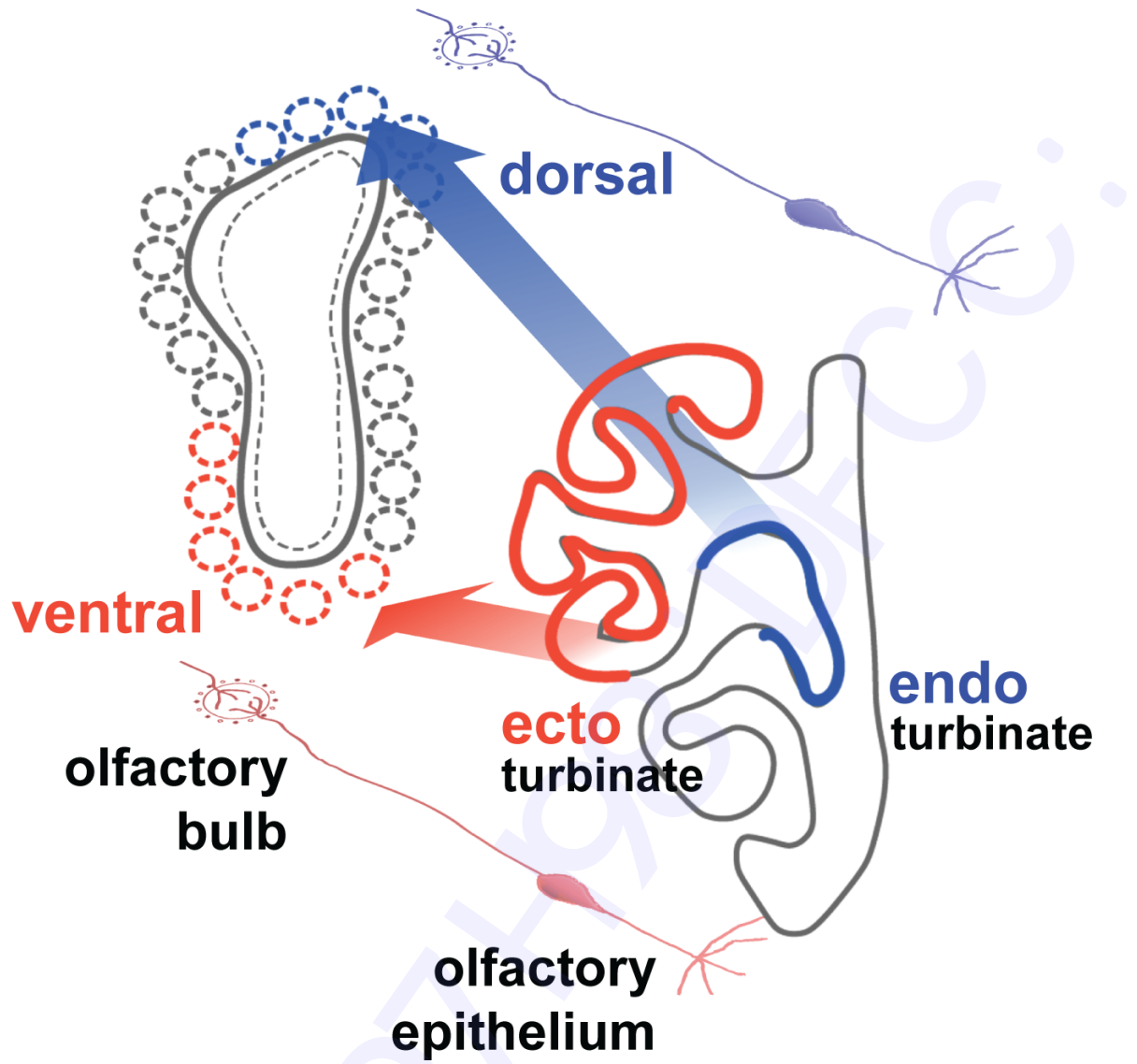


Fig. 2.